

Bisphosphonates and low-impact femoral fractures: Current evidence on alendronate-fracture risk

Jennifer P. Schneider, MD, PhD

Several recent medical articles have described multiple cases of unusual low-impact subtrochanteric stress fractures or completed fractures of the femur in patients who have been on the bisphosphonate alendronate for several years for osteoporosis or osteopenia. Some patients have experienced such fractures in both femurs. The fractures are often preceded by pain in the affected thigh, may have a typical x-ray appearance, and many have delayed healing. It has been hypothesized that in some patients, long-term alendronate causes oversuppression of bone turnover, resulting in bones that are brittle despite improved bone density. In patients with atypical or low-impact fractures of the femoral shaft, consider the possible connection with alendronate use. Some bone specialists now recommend stopping alendronate in most patients after 5 years.

Schneider JP. Bisphosphonates and low-impact femoral fractures: Current evidence on alendronate-fracture risk. *Geriatrics*. 2009;64(1):18-23.

Key words: atypical fracture, femoral shaft, low-impact fracture, oversuppression, subtrochanteric

Drugs discussed: alendronate, ibandronate, pamidronate, risedronate, teriparatide, zoledronic acid

Dr Schneider practices internal medicine and pain management in Tucson, Arizona.

Disclosure: As she was the patient in a related 2006 *Geriatrics* case report, the author discloses that she has a personal interest in understanding the possible causative role of alendronate and atypical femoral fractures. She states that she has no financial interests in any pharmaceutical product used to treat osteoporosis.

A 66-year old, previously healthy woman developed a spontaneous stress fracture of her right foot, which eventually healed. Nine months later she took a step in her bedroom and collapsed to the floor. An x-ray revealed a nontraumatic fracture of her right femur. She underwent surgery with placement of an intramedullary rod. Her physician told her she had most likely had a stress fracture, which became a completed fracture. A bone scan done shortly after her surgery revealed a stress fracture of her left femur. Some months later she underwent prophylactic rodding of the left femur. The patient had been on alendronate for 7 years.

A 65-year woman visiting Europe stepped off the bottom step of a van and collapsed. An x-ray revealed a nontraumatic fracture of her left femur. She had been experiencing a dull ache in her left femur for some months. The patient underwent placement of an intramedullary rod. One year later she developed a dull ache in her right femur. A bone scan showed a stress fracture in the right femur. A bone specialist recommended prophylactic rodding of the right femur, which was done. The patient had been on alendronate for 9 years.

A 59-year-old-woman took a step, her right leg gave out, and she fell to the ground as she heard her leg break. Her femur was fractured. The orthopedic surgeon on call told her, "We don't usually see this type of fracture without trauma." For the preceding year she'd experienced pain in her right thigh, which was severe enough to cause limping. An x-ray had been negative, and her primary care physician thought she had fibromyalgia. She had been on alendronate for more than 5 years.

These unpublished case reports, and several other similar ones, were sent to the author following publication of a 2006 report in *Geriatrics*¹ of a 59-year-old, previously healthy woman who, while riding on a subway train, suffered a comminuted spiral fracture of the right femur when the train jolted (see figure, page 20). The patient had been experiencing pain in her right thigh for 3 months. A bone scan a week before the fracture showed a stress fracture of the right femur. The patient had been taking alendronate, 70 mg/week, for approximately 7 years for osteopenia, as well as calcium plus hormone replacement therapy. Despite pro-

longed use of an electrical bone stimulator, and cessation of alendronate use, the fracture did not unite. After 9 months, the patient had a second surgical procedure to replace the original rod with a larger one. After a delay, the bone finally united. The author suggested a possible causal relationship between long-term alendronate and the femoral fracture.

Fragility fractures of the proximal femur are rare. However, in the past 3 years, multiple additional cases like those above have been published and the evidence continues to grow that in a small subpopulation of patients, long-term alendronate use may be related to low-impact, nontraumatic, or “atypical” fractures of the femur, often with delayed healing. This paper reviews the older evidence for a connection between bisphosphonates and bone fragility, and summarizes recent reports and recommendations.

Femoral fractures and alendronate

Bisphosphonates are considered first-line treatment for postmenopausal osteoporosis. They are prescribed for millions of geriatric patients. Bisphosphonates—alendronate (Fosamax), risedronate (Actonel), ibandronate (Boniva), and zoledronic acid (Zometa, Reclast)—inhibit bone resorption by decreasing the activity of osteoclasts. Extensive studies have shown that therapy with bisphosphonates improves bone density and decreases fracture risk.²⁻⁶ When discontinued after 5 years, the physiologic effect of alendronate continues for at least 5 years, with no increase in morphometric vertebral fracture risk or in the risk of nonvertebral fractures compared with patients who continued to take alendronate for the full 10 years.⁷ This result is consistent with the fact that alendronate is incorporated into bone matrix and has a biological half-life of more than 10 years.

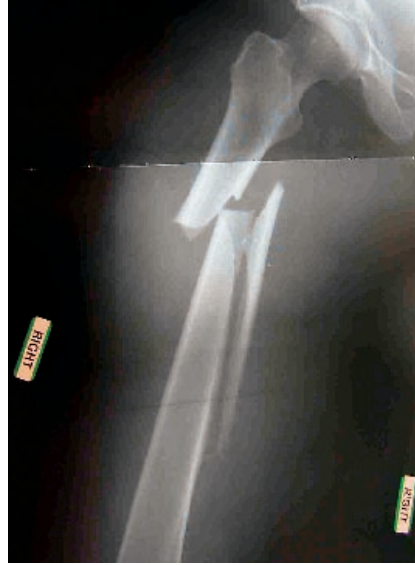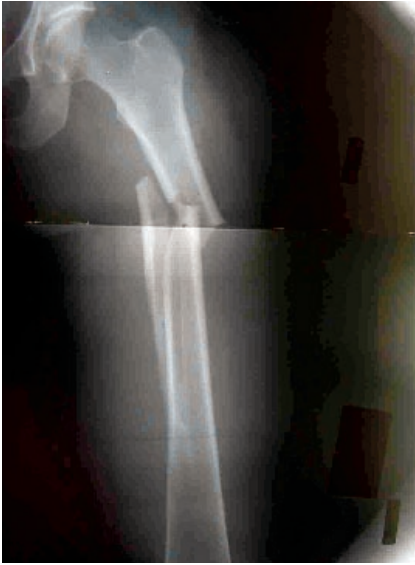Bone turnover is a natural part of maintaining bone health. When bone turnover is inhibited by bisphosphonates, microdamage that occurs regularly in bone but is normally repaired might accumulate after long-term use. There have long been concerns about the long-term safety of bisphosphonates because of their potential to cause oversuppression of bone turnover.⁸⁻¹³ The first report suggestive of the clinical relevance of these hypothetical concerns was published in 2005 by Odvina et al,¹⁴ describing 8 postmenopausal women and a man who sustained unusual nontraumatic nonspinal fractures while on alendronate therapy for 3-8 years. All 9 continued taking alendronate after the fracture. Six of the 9 patients had delayed or absent fracture healing for 3 months to 2 years during continued alendronate therapy. All 9 patients underwent iliac crest biopsy of trabecular bone. All the specimens showed markedly suppressed bone formation. The authors concluded that long-term alendronate therapy may result in severe suppression of bone turnover, with increased susceptibility to nonspinal fractures along with delayed healing.

In 2007 a group from Singapore published a retrospective review of patients admitted with a low-energy subtrochanteric fracture (defined as one in the region of the femur that extended from the lesser trochanter to the junction of the proximal and middle third of the femoral shaft.)¹⁵ Of 13 women identified, 9 were on long-term alendronate therapy (mean 4.2 years, range 2.5-5). Their average age was 67 years, versus 80 years in the non-alendronate group. Four of the 9 patients in the alendronate group reported that the fracture had occurred in the absence of a fall. Five patients reported experiencing prodromal

pain in the fractured limb, starting 2-6 months before the injury; none of the patients in the non-alendronate group had prodromal symptoms. In 6 patients in the alendronate group, cortical hypertrophy was identified on the lateral side of the subtrochanteric region of the femur, and 3 of these also had cortical hypertrophy on the contralateral femur.

Long-term alendronate therapy may suppress bone turnover.

The Singapore group recently elaborated on its findings with a retrospective review of postmenopausal patients with subtrochanteric insufficiency fractures admitted to their hospital over a 20-month period.¹⁶ They found 17 patients, whose mean age was 66 years, and all had been taking alendronate, for a mean of 4.4 years (range 2.2-8), except for one patient who was on risedronate for 6 years after 4 years of alendronate. All fractures were low-energy, typically sustained after tripping. Seven of the patients reported experiencing acute pain before they fell, suggesting that the fracture preceded the fall. Thirteen of the 17 patients (76%) had experienced prodromal pain in the affected thigh ranging from 1 week to 2 years before the fracture. Often these patients had been treated for referred pain from a spinal origin, without improvement. Three patients had sustained prior contralateral femoral fractures 2-4 years earlier but had been continued on their bisphosphonate; the patient who was switched to risedronate was one of these. Five other patients had stress reactions seen on plain x-rays in the contralateral femurs; a bone scan of one of these patients showed abnormal uptake in that femur. Pointing to



X-ray of comminuted spiral fracture involving upper half of right femur.

the incidence of bilateral stress reactions and fractures in more than half of their patients, the authors conclude that these patients have a systemic disorder reflecting oversuppression of bone turnover rather than localized pathology. They advise cautious administration of alendronate in osteoporosis management, and “in situations where the characteristic subtrochanteric fractures have already developed, physicians should strongly consider discontinuing the drug.”

In 2008 a group from the Hospital for Special Surgery, an orthopedic hospital in New York City, published 2 reports of patients taking alendronate who had atypical fractures of the femur. One report focused on a specific radiographic pattern.¹⁷ The authors described 15 postmenopausal women who had been receiving alendronate for a mean of 5.4 years and who presented with atypical low-energy fractures, defined as fractures occurring in a fall from a standing height or less. Ten of the 15 had a unique radiographic pattern, a simple transverse or oblique fracture with beaking of the cortex and diffuse cortical thickening of the proximal femoral shaft. All the

patients with this pattern also had cortical thickening of the contralateral femur and 3 had had a prior femoral fracture; none of the patients had a history of vertebral fractures. The authors conclude that these 10 women may represent a subgroup of the population that is more susceptible to the effects of prolonged suppression of bone turnover. They call for a prospective study to characterize this subgroup.

A case is made for discontinuing alendronate.

The same group also reported on a retrospective review of patients with femoral shaft fractures (including the 15 in the prior report) admitted between January 2002 and March 2007.¹⁸ Seventy low-energy fractures were identified, in 59 females and 11 males, with an average age of 74.7 years. Osteoporosis was present in 44% of the 70 patients. Twenty-five patients (36%), all women, were being treated with alendronate, 84% for osteoporosis; none of the patients had used any other

bisphosphonate. Of the 25, 19 (76%) had a specific pattern to the fracture—it was transverse, with a one-sided beak in an area of thickening of the cortex. This fracture pattern was seen in only 1 patient (2%) of patients not being treated with alendronate. The odds ratio for this pattern was 139.33 for alendronate users, and was 98% specific to identifying alendronate users. The patients with this pattern had been using alendronate for a mean of 6.9 years. The authors concluded that although they have not established a causal relationship, such fractures may result from propagation of a stress fracture whose repair is retarded by decreased osteoclast activity and impaired microdamage repair resulting from the prolonged use of alendronate. Minimal trauma is then required to produce a completed fracture.

Discussion

Fragility or insufficiency fractures are a type of stress fracture that occurs in osteoporotic bone subjected to normal levels of stress. They typically occur in the vertebrae, hip, distal radius, and the proximal humerus following minimal or no trauma, but only rarely in the proximal femur.¹⁹ The subtrochanteric region of the femur is one of the strongest parts of the femur and it is unlikely to fracture in low low-energy trauma unless extreme osteoporosis is present.¹⁵ The reports of multiple cases of low-impact femoral fractures in patients who were taking alendronate for several years, a previously rare event, have therefore called for further study of the possible connection between alendronate and such fractures, as has been suggested by several authors.

Alendronate is stored in the bone for many years and is reactivated as bone is turned over and the drug re-enters the circulation. Patients on long-term alendronate who experienced completed fractures of the femur with minimal

trauma continue to be at risk of additional insufficiency fractures. In those in whom a stress fracture was subsequently diagnosed in the contralateral femur, prophylactic surgical rodding is typically suggested in order to prevent a completed fracture. Some bone specialists treat such patients with teriparatide (recombinant human parathyroid hormone [Forteo]) in an attempt to reverse their adynamic bone. Unlike bisphosphonates, which work by decreasing the activity of osteoclasts that break down bone, recombinant PTH strengthens bone and improves bone density by increasing the activity of osteoblasts that build bone. Teriparatide stimulates bone formation, increases bone mass, and improves bone microarchitecture.²⁰ In patients previously treated with alendronate or raloxifene, subsequent treatment with teriparatide significantly increased bone turnover, although less so in patients formerly on alendronate.^{21,22} This drug is recommended by Lenart et al of the New York City group in a recent published letter²³ based on findings of the effects of parathyroid hormone and alendronate alone or in combination in postmenopausal osteoporosis.⁷ Results of treatment with teriparatide in women with alendronate-related insufficiency fractures will be published in the near future.²⁴ Teriparatide should not be used in patients who are at an increased risk of developing bone tumors (eg, patients with Paget's disease, unexplained elevations of alkaline phosphatase, open epiphyses, or prior radiation therapy involving the skeleton).

Osteonecrosis of the jaw

The evolution of our understanding of the relationship between alendronate and femoral fractures parallels the growing understanding of the relationship between use of bisphosphonates and osteonecrosis of the jaw (ONJ), which may reflect a similar mechanism of bone injury. After numerous

publications of multiple case reports, a population-based analysis of IV bisphosphonate therapy concluded that the hazard ratio of being diagnosed with inflammatory conditions or osteomyelitis of the jaw was 11.48 for recipients of IV bisphosphonates as compared with non-recipients.²⁵ No randomized, controlled, double-blind studies have been done regarding bisphosphonates and ONJ, and they are unlikely to be done in the future. Nonetheless, the case reports and population studies have led to the creation of a new syndrome in the dental world, bisphosphonate-associated osteonecrosis of the jaw (BON), and position papers on trying to prevent this disorder have been published by several organizations concerned with dental surgery.

Bisphosphonates, osteonecrosis of jaw may be linked.

Although most cases of ONJ have occurred in patients treated with IV bisphosphonates (pamidronate, zoledronic acid), the finding of some cases related to oral bisphosphonates resulted in the recent publication by the American Dental Association of "Dental management of patients receiving oral bisphosphonate therapy."²⁶ This document suggests that "because there is no validated diagnostic technique currently available to determine if patients are at increased risk for developing BON, it may be prudent to proceed conservatively in some cases." For example, if full-mouth tooth extraction is needed, begin by extracting one tooth and see if the jaw heals. The Association of Oral and Maxillofacial Surgeons published guidelines in 2006 that state, "If systemic conditions permit, it has

been proposed that discontinuation of oral bisphosphonates for a period of 3 months prior to and 3 months following elective invasive dental surgery may lower the risk of bisphosphonate-related ONJ."²⁷ There are no actual data as yet to help determine the appropriate length of time the patient should be off the bisphosphonate, and this depends on the particular drug.

Nonetheless, the dental profession's current guidelines are a model for prudent, patient-centered care in an environment where definitive high-grade studies are lacking but where there are reports of multiple, difficult-to-treat cases strongly suggestive of a bisphosphonate cause. There is already a published case report in the dental literature of a refractory case of ONJ that was successfully treated with teriparatide.²⁸

Recommendations

Citing the 2006 report by Black et al⁷ about stopping or continuing alendronate after 5 years of treatment, the National Osteoporosis Foundation (NOF), in its Clinical Update Online of July 2008, said, "Results suggest that for most women, taking a 5-year 'drug holiday' after being on alendronate (5-10 mg/day) for 5 years does not increase fracture risk and might be advantageous. For women at high risk for vertebral fractures, continuing alendronate for a total of 10 years is a reasonable clinical option."²⁹

In 2008 the NOF published a Clinician's Guide to Prevention and Treatment of Osteoporosis. This guide introduced a new Fracture Risk Algorithm (FRAX) for calculating which men and women over 50 require pharmacologic treatment for osteoporosis. The report states that FRAX analyses generally confirm that it is cost-effective to treat individuals with a prior hip or vertebral fracture and those with a DEXA femoral neck -T score of -2.5 or worse.

The guide does not discuss the recommended duration of treatment with bisphosphonates. It does discuss the usefulness of biochemical markers of bone metabolism, saying, "Suppression of biochemical markers of bone turnover after 3-6 month of specific antiresorptive osteoporosis therapies, and biochemical marker increases after 1-3 months of specific anabolic therapies, have been predictive of greater BMD responses in studies evaluating large groups of patients. Because of the high degree of biological and analytical variability in measurement of biochemical markers, changes in individuals must be large in order to be clinically meaningful."³⁰

More study is needed on outcomes, durations of bisphosphonates.

The North American Menopause Society (NAMS), in its 2006 position statement on management of osteoporosis in post-menopausal women, says, "Current evidence does not support recommendations regarding the optimal duration of bisphosphonate therapy."³¹

In the absence of definite guidelines from NOF or NAMS, some bone metabolism specialists are increasingly suggesting that alendronate use be stopped in most cases after 5 years, despite the absence of randomized prospective studies.¹⁴ Patients should continue weight-bearing activities, calcium and Vitamin D, and undergo periodic DEXA scanning. Those with a high fracture risk might best be served by continuing treatment with a bisphosphonate or treatment with an alternative agent, such as teriparatide. As implied by the recent NOF guidelines, it might be prudent to withhold initiating bisphosphonates in otherwise healthy postmenopausal women who merely

have osteopenia, saving these drugs for those who have osteoporosis.

There may be a group of patients with low bone density who should not be treated with bisphosphonates. At present there is no way of predicting who these patients are. There is a need for research designed to identify those patients who are potentially at risk for adverse outcomes with bisphosphonates in general, or with alendronate in particular. These patients undoubtedly constitute a small percentage compared to those who benefit from bisphosphonates, but for those patients these fractures can be devastating events, to be prevented if at all possible.

Population research is also needed that compares the incidence of subtrochanteric fractures among people being treated with alendronate with the incidence among a group with comparable bone density who have not been treated with alendronate. This remains to be done. In September 2008 at a bone research meeting, researchers reported a large Danish registry cohort analysis showing that alendronate use was indeed significantly associated with an increased risk of atypical subtrochanteric fractures.³² The alendronate group had an incidence of subtrochanteric fractures of 2.9/1,000 patient years, compared with only 1.6 among the controls. However, regular hip fractures were also significantly more common among the alendronate group, suggesting that the alendronate-treated group had weaker bones than controls in the first place. Clearly, additional population studies are needed.

It is uncertain whether all bisphosphonates have the potential risk of suppressing bone repair, or only alendronate. Alendronate was the first bisphosphonate available and still the most widely used. Its long biological

half life might make it more likely than other bisphosphonates to cause problems in susceptible patients. Physicians need to be aware that patients on bisphosphonates who experience low-impact femoral fractures may require additional evaluation and treatment along with surgical fixation. This might include bone scans to detect other stress fractures, stopping alendronate therapy, and referral to specialists knowledgeable in treating these unusual cases.

References

- Schneider JP. Should bisphosphonates be continued indefinitely? An unusual fracture in a healthy woman on long-term alendronate. *Geriatrics*. 2006;61(1):31-33.
- Cummings SR, Black DM, Thompson DE et al. Effect of alendronate on risk of fracture in women with low bone density but without vertebral fractures: Results from the Fracture Intervention Trial. *JAMA*. 1998;280(24):2077-2082.
- Pols HA, Felsenberg D, Hanley DA, et al. Multinational, placebo-controlled, randomized trial of the effects of alendronate on bone density and fracture risk in postmenopausal women with low bone mass: Results of the FOSIT study. *Osteoporos Int*. 1999;9(5):461-468.
- Tonino RP, Meunier PJ, Emkey R, et al. Skeletal benefits of alendronate: 7-year treatment of postmenopausal osteoporotic women. *J Clin Endoc Metab*. 2000;85(9):3109-3115.
- Black DM, Thompson DE, Bauer DC, et al. Fracture risk reduction with alendronate in women with osteoporosis: The Fracture Intervention Trial FIT Research Group. *J Clin Endocrinol Metab*. 2000;85(11):4118-4124. Erratum in: *J Clin Endocrinol Metab*. 2001;86(2):938.
- Orwoll E, Ettinger M, Weiss S, et al. Alendronate for the treatment of osteoporosis in men. *N Eng J Med*. 2000;343(9):604-610.
- Black DM, Schwartz AV, Ensrud KE, et al. Effects of continuing or stopping alendronate after 5 years of treatment: The Fracture Intervention Long-term extension (FLEX): A randomized trial. *JAMA*. 2006;296:2927-2938.
- Mashiba T, Turner CH, Hirano T, et al. Effects of suppressed bone turnover by bisphosphonates on microdamage accumulation and biomechanical properties in clinically relevant skeletal sites in beagles. *Bone*. 2001;28(5):524-531.
- Hirano T, Turner CH, Forwood MR, et al. Does suppression of bone turnover impair mechanical properties by allowing microdamage accumulation? *Bone*. 2000;22(1):13-20.
- Boivin G, Meunier PJ. Changes in bone remodeling rate influence the degree of

ALENDRONATE-FRACTURE RISK

- mineralization of bone. *Connect Tiss Res.* 2002;43(2-3):535-537.
11. Akkus O, Polyakova-Akkus, Adar F, Schaffler MB. Aging of microstructural compartments in human compact bone. *J Bone Miner Res.* 2003;18(6):1012-1019.
 12. Ciarelli TE, Fyhrie DP, Parfitt AM. Effects of vertebral bone fragility and bone formation on the mineralization levels of cancellous bone from white females. *Bone.* 2003;32(3):311-315.
 13. O'Brien FJ, Brennan O, Kennedy OD, Lee TC. Microcracks in cortical bone: How do they affect bone biology? *Curr Osteoporos Rep.* 2005 Jun;3(2):39-45.
 14. Odvina CV, Zerwekh JE, Rao DS, et al. Severely suppressed bone turnover: A potential complication of alendronate therapy. *J Clin Endocrinol Metab.* 2005;90(3):1897-1899.
 15. Goh SK, Yang KY, Koh JS, et al. Subtrochanteric insufficiency fractures in patients on alendronate therapy: A caution. *J Bone Joint Surg Br.* 2007;89:349-353.
 16. Kwek EB, Goh SK, Koh JS, et al. An emerging pattern of subtrochanteric stress fractures: A long-term complication of alendronate therapy? *Injury.* 2008;39(2):224-231.
 17. Lenart BQ, Lorch CG, Lane JM. Atypical fractures of the femoral diaphysis in postmenopausal women taking alendronate. *N Engl J Med.* 2008;358(12):1304-1306.
 18. Neviasser AS, Lane JM, Lenart BA, et al. Low-energy femoral shaft fractures associated with alendronate use. *J Orthop Trauma.* 2008;22(5):346-350.
 19. Gibson MV. Evaluation and treatment of bone disease after fragility fracture. *Geriatrics.* 2008;63(7):21-30.
 20. McClung M, San Martin J, Miller PD, Civitelli R, et al. Opposite bone remodeling effects of teriparatide and alendronate in increasing bone mass. *Arch Int Med.* 2005;1762-1768.
 21. Ettinger B, San Martin J, Crans G, Pavo I. Differential effects of teriparatide on BMD after treatment with raloxifene or alendronate. *J Bone Miner Res.* 2004;19:745-751.
 22. Miller PD, Delmas PD, Lindsay R, Watts NB, et al. Early responsiveness of women with osteoporosis to teriparatide after therapy with alendronate or risedronate. *J Clin Endocrinol Metab.* 2008 Oct;93(10):3785-93.
 23. Lenart BA, Lorch DG, Lane JM. More on atypical fractures of the femoral diaphysis. Letter. *N Engl J Med.* 2008;359(3):317-318.
 24. Miller P. Personal communication. July 2008.
 25. Wilkinson GS, Kuo Y-F, Freeman JL, Goodman JS. Intravenous bisphosphonate therapy and inflammatory conditions or surgery of the jaw: A population-based analysis. *J Nat Cancer Inst.* 2007;99:1016-24.
 26. Dental management of patients receiving oral bisphosphonate therapy: Report of the Council on Scientific Affairs. 1 July 1998. American Dental Association web site. http://www.ada.org/prof/resources/topics/topics_osteonecrosis_bisphosphonate_report.pdf. Accessed September 6, 2008.
 27. Position Paper on Bisphosphonate-Related Osteonecrosis of the Jaw. 2006. American Association of Oral and Maxillofacial Surgeons web site. http://www.aaoms.org/docs/position_papers/osteonecrosis.pdf. Accessed September 12, 2008.
 28. Harper RP. Resolution of bisphosphonate-associated osteonecrosis of the mandible: Possible application for intermittent low-dose parathyroid hormone [rhPTH(1-34)]. *J Oral Maxillofac Surg.* 2007;65:573-580.
 29. Update on Bisphosphonates FDA-Approved for Prevention and Treatment of Osteoporosis. July 2008. National Osteoporosis Foundation web site. <http://www.nof.org>. CUOnline-July08-forweb.pdf. Accessed January 2, 2009.
 30. Clinician's Guide to Prevention and Treatment of Osteoporosis. National Osteoporosis Foundation web site. http://www.nof.org/professionals/cliniciansguide_form.asp. Accessed January 2, 2009.
 31. North American Menopause Society Position Statement: Management of osteoporosis in postmenopausal women, 2006. *The Journal of the North American Menopause Society.* 13(3):340-367.
 32. ASBMR: Alendronate Exonerated in 'Atypical' Femoral Fractures. September 15, 2008. MedPage Today web site. <http://www.medpagetoday.com/MeetingCoverage/ASBMR/10904>. Accessed September 22, 2008.



industry matter

Practice Management Toolkit


Practical Information and Expert Advice
You Need to Manage Your Practice

Discover How-To:

- Boost your bottom line
- Add services without big debt
- Market your practice
- Provide staff benefits that won't cost a bundle
- Avoid a threat worse than Malpractice
- and much more ...



Your Price \$149.95



WEB SEMINAR CD

Vital Signs of a
Healthy Practice

Your Price \$99.95



A Handbook to
Marketing Your Practice

Your Price \$24.95



8 AUDIO
CD SET

27 Proven Marketing
Strategies to Boost Your
Practice Profits

Your Price \$199.00



Adding Ancillary Services
Combo

Your Price \$59.95

CONTEMPORARY
OB/GYN

pediatrics

Medical
Economics

DermatologyTimes

OphthalmologyTimes

Cosmetic
SurgeryTimes

Geriatrics

UrologyTimes

888-480-0580

www.industry-matter.com/healthcare.aspx

Click. Shop. Learn.