

Should bisphosphonates be continued indefinitely?

An unusual fracture in a healthy woman on long-term alendronate

Jennifer P. Schneider, MD, PhD

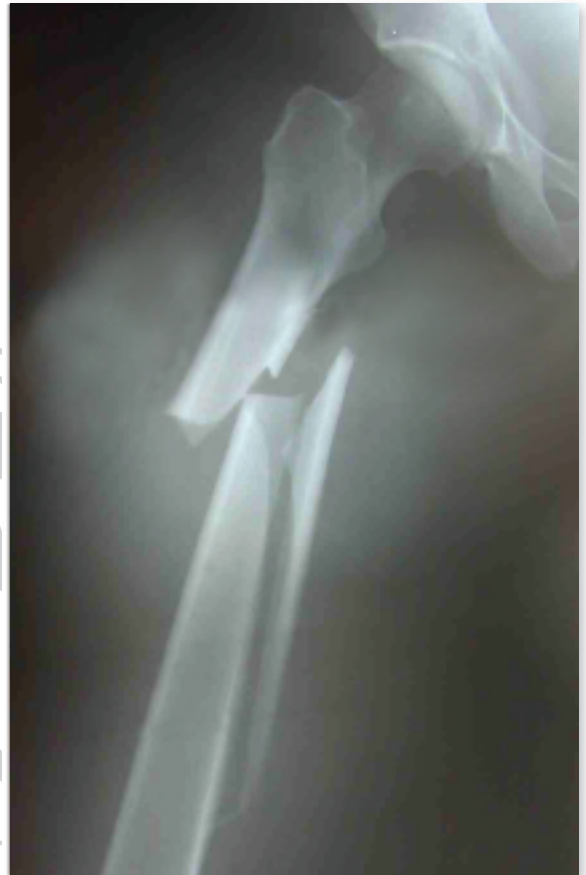A 59-year old previously healthy woman visiting New York City was riding a subway train one morning when the train jolted. She shifted all her weight to one leg, felt a bone snap, and fell to the floor of the train. A hip x-ray in a local emergency department revealed a comminuted spiral fracture involving the upper half of the right femur (see figure). The woman was transferred to an orthopedic hospital, where she was noted to be 5'9" tall, 155 pounds, and in a great deal of pain. She had no significant medical problems aside from osteoarthritis of the knees and thumbs. Her medications consisted of hormone replacement therapy and alendronate, 70 mg/week. She had been taking alendronate for approximately seven years.

The patient had experienced early menopause at age 42 and began hormone replacement therapy (HRT) at that time. At age 52 she had a dual energy x-ray absorptiometry bone density (DXA) scan, which showed a T-score at the lumbar spine of -2.0 . This finding, along with a strong family history of osteoporosis, led to the addition of alendronate to her HRT regimen. Follow-up DXA scans showed

significant improvement in her bone density. (A DXA scan done 3 months after the fracture showed a spinal mean T score at L2-L4 of -0.6 , and a total femoral T score of -0.9 , with the femoral neck showing a T score of -1.4)

Her only prior fracture history was a skiing accident at age 24 resulting in fractures of her left tibia, fibula, and wrist, all of which healed uneventfully with casting. One day, three months prior to the subway accident, however, she had begun to experience moderate pain in her right thigh with every step. There was no preceding trauma, nor any recent increase in her physical activity. An x-ray of her right femur was

read as "There is slight thickening of the cortex of the right femur laterally, significance uncertain. Suspect this is simply normal variation." Because the pain persisted, a bone scan was done, and it was read as "Intense focus of radionuclide uptake in the proximal right femur correlating with a focal area of cortical thickening. This finding is very suggestive of a possible underlying osteoid osteoma. Radiographs reveal no



The case patient's hip x-ray showing a comminuted spiral fracture involving the upper half of the right femur.

X-ray courtesy of the author.

other changes of lytic disease or blastic disease that would suggest primary or secondary neoplastic disease." The bone scan was done one week prior to the occurrence of the fracture. An MRI of the femur was ordered for two weeks hence; however, because of a family emergency, the patient flew to New York before the date of the scheduled MRI.

Because the fracture preceded the pa-

Dr. Schneider is certified in internal medicine, addiction medicine, and pain management; she practices in Tucson, AZ

Disclosure: Dr. Schneider reports no conflict of interest.

Case Report

tient's fall, it was thought likely that she had a pathologic fracture, perhaps secondary to some metastatic lesion. She was therefore placed in traction and underwent extensive CT scanning of the chest, abdomen, pelvis, lumbar spine, and the femur, as well as plain x-rays, which revealed no evidence of pathological disease consistent with metastatic or primary lesion suggestive of carcinoma. Three days later, an intramedullary titanium rod was placed. The opinion of the orthopedic surgeons after they reviewed the out-of-state x-ray and bone scan was that it was typical of a stress fracture. The jolt in the moving subway train completed the fracture.

In the months following, it became clear that the fracture was not uniting. Physical therapy and an extensive trial of an external electrical bone stimulator did not result in significant union of the fracture. An orthopedic trauma specialist recommended the patient undergo a "revision intramedullary rodding procedure with use of a recon-type nail to aid in fixation of the proximal fragment." The surgery was done nine months after the initial fracture.

At the time of her initial hospitalization, the patient was told to stop her HRT because of risk of deep-vein thrombophlebitis (DVT) related to her immobilization. She asked about continuing the alendronate, since she was concerned that its suppression of bone turnover might inhibit healing of the fracture. She was told that although this was a theoretical possibility, there was no evidence to that effect, so that there was no reason to stop the drug. However, after months of delayed healing, the patient chose to stop the alendronate. After the second procedure, there was some delay in healing, but by 6 months it was clear that the fracture was uniting. Two years after her first symptoms of a stress fracture of the femur, she was finally able to get back to her usual level of physical activity.

After more than two years off alendronate therapy, a DXA scan showed some decrease in bone density, and the

Table Bisphosphonates approved for osteoporosis

Agent	dose
Alendronate (Fosamax)	70 mg once a week
Risedronate (Actonel)	35 mg once a week
Ibandronate (Boniva)	150 mg per month

Source: Created for Geriatrics by JP Schneider, MD, PhD.

patient was advised to resume taking the drug. One year later, she awoke to find that she had moderate pain in her right foot with every step. There was no preceding trauma nor any increase in activity. The possibility of another nontraumatic stress fracture was considered and again the bisphosphonate therapy was stopped. Two months later, a bone scan showed intense uptake in the second metatarsal bone, consistent with a stress fracture. The patient continued taking calcium supplements, 500 mg/bid, and an estrogen/progesterone combination, 1 mg/d, and walking one mile daily wearing sturdy shoes to support her foot. After several months, the fracture healed.

Studies show that therapy with bisphosphonates improves bone density, decreases fracture risk

Discussion

This case report describes a previously healthy woman who experienced two nontraumatic stress fractures, four years apart, while on alendronate therapy, and also nonunion of the spiral femoral fracture that resulted from the stress fracture. A spontaneous stress fracture of the femur is so unusual that neither her orthopedic surgeon nor the radiologist who

read the bone scan even considered that diagnosis in their differential. Consequently, the patient was never cautioned about her vulnerability to sustain a completed fracture.

Bisphosphonates—such as alendronate, risedronate, and ibandronate—are inhibitors of bone resorption. Extensive studies have shown that therapy with bisphosphonates improves bone density and decreases fracture risk.¹⁻⁵ These drugs, especially the oldest one, alendronate, are used by large numbers of postmenopausal women, as well as smaller numbers of men with idiopathic, steroid-induced, hypogonadal, or other causes of osteoporosis. Combined use of bisphosphonates and estrogen gives even greater improvement in bone density.⁶⁻⁸


Increased bone density does not necessarily equate with good bone quality, however. Bone turnover is a natural part of maintaining bone health. By decreasing osteoclast activity and bone resorption—and therefore bone formation as well—microdamage that occurs regularly in bone but is normally repaired might accumulate after long-term use. There have long been concerns about the potential oversuppression of bone turnover during long-term use of bisphosphonates and therefore their long-term safety.⁹⁻¹⁴ The concern is increased when the bisphosphonate is taken concurrently with another agent that may inhibit bone turnover, such as estrogen. The current patient package insert (PPI) for Fosamax (alendronate) states, "The long-term effects of combined Fosamax and HRT on fracture occurrence and fracture healing have not been studied." Clearly, such studies are needed.

Recently, Odvina and colleagues¹⁴ re-

ported on 9 patients, 8 postmenopausal women and 1 man, who sustained unusual spontaneous nonspinal fractures while on alendronate therapy (10 mg/d or 70 mg/week) for 3 to 8 years. Three of the 8 women were also on HRT. The present case report above fits into this category of patient. All 9 patients continued taking alendronate after the fractures. Six of the 9 patients had delayed or absent fracture healing for 3 months to 2 years during alendronate therapy.

All the patients had iliac crest biopsies of trabecular bone. The biopsy specimens underwent histomorphometric analysis using tetracycline labeling to study bone metabolic activity. All patients showed markedly suppressed bone formation, with reduced or absent osteoblastic surface in most patients. Ma-

despite bisphosphonate therapy could be considered for treatment with intermittent PTH (parathyroid hormone). In otherwise healthy, perimenopausal women, who merely have osteopenia, the best therapeutic option is not clear.”

What should we advise our patients? Bisphosphonates are stored in bone for up to 10 years after their consumption is stopped, although their metabolic effects are of shorter duration. Studies have shown the efficacy of bisphosphonates in the first five years of therapy in improving bone density and diminishing the risk of fractures.^{6,7,8} After that, until additional studies are done that clarify the risks of nontraumatic fractures and delayed healing in patients on long-term bisphosphonates, and which risk factors, if any, can help predict which patients are at increased risk of these adverse events, it is reasonable to suggest that patients consider stopping the drug after several years, continue weight-bearing exercise and calcium, and wait to see what the next scheduled DXA scan shows. 

Current evidence suggests that bisphosphonates be stopped after 5 years

trix synthesis was markedly diminished.

The authors concluded that during long-term alendronate therapy, severe suppression of bone turnover may occur, resulting in increased susceptibility to nonspinal fractures along with delayed healing. “Although coadministration of estrogen or glucocorticoids appears to be a predisposing factor, this apparent complication can also occur with monotherapy.”

In an editorial accompanying the Odvina article, Dr. Susan Ott¹⁵ notes that the bone biopsies showed more suppression than predicted by the biochemical markers. She concludes, “I believe the current evidence suggests that bisphosphonates should be stopped after 5 years. Those patients who remain at a high risk of fractures or who have had fractures

Metab 2000; 85(11):4118–24.

- Orwoll E, Ettinger M, Weiss S, et al. Alendronate for the treatment of osteoporosis in men. *N Engl J Med* 2000; 343(9):604–10.
- Ravn P, Bidstrup M, Wasnich RD, et al. Alendronate and estrogen-progestin in the long-term prevention of bone loss: Four-year results from the early postmenopausal intervention cohort study: A randomized, controlled trial. *Ann Intern Med* 1999; 131(12):935–42.
- Bone HG, Greenspan SL, McKeever C, et al. Alendronate and estrogen effects in postmenopausal women with low bone mineral density. Alendronate/Estrogen Study Group. *J Clin Endocrinol Metab* 2000; 85(2):720–6.
- Lindsay R, Cosman F, Lobo RA, et al. Addition of alendronate to ongoing hormone replacement therapy in the treatment of osteoporosis: A randomized, controlled clinical trial. *J Clin Endocrinol Metab* 1999; 84(9):3076–81.
- Mashiba T, Turner CH, Hirano T, Forwood MR, Johnston CC, Burr DB. Effects of suppressed bone turnover by bisphosphonates on microdamage accumulation and biomechanical properties in clinically relevant skeletal sites in beagles. *Bone* 2001; 28(5):524–31.
- Hirano T, Turner CH, Forwood MR, Johnston CC, Burr DB. Does suppression of bone turnover impair mechanical properties by allowing microdamage accumulation? *Bone* 2000; 27(1):13–20.
- Boivin G, Meunier PJ. Changes in bone remodelling rate influence the degree of mineralization of bone. *Connect Tissue Res* 2002; 43(2–3):535–7.
- Akkus O, Polyakova-Akkus A, Adar F, Schaffler MB. Aging of microstructural compartments in human compact bone. *J Bone Miner Res* 2003; 18(6):1012–9.
- Ciarelli TE, Fyhrie DP, Parfitt AM. Effects of vertebral bone fragility and bone formation rate on the mineralization levels of cancellous bone from white females. *Bone* 2003; 32(3):311–5.
- Odvina CV, Zerwekh JE, Rao DS, et al. Severely suppressed bone turnover: A potential complication of alendronate therapy. *J Clin Endocrinol Metab* 2005; 90(3):1294–301.
- Ott SM. Editorial: Long-term safety of bisphosphonates. *J Clin Endocrinol Metab* 2005; 90(3):1897–99.

References

- Cummings SR, Black DM, Thompson DE, et al. Effect of alendronate on risk of fracture in women with low bone density but without vertebral fractures: Results from the Fracture Intervention Trial. *JAMA* 1998; 280(24):2077–82.
- Pols HA, Felsenberg D, Hanley DA, et al. Multinational, placebo-controlled, randomized trial of the effects of alendronate on bone density and fracture risk in postmenopausal women with low bone mass: Results of the FOSIT study. *Fosamax International Trial Study Group. Osteoporos Int* 1999; 9(5):461–8.
- Tonino RP, Meunier PJ, Emkey R, et al. Skeletal benefits of alendronate: 7-year treatment of postmenopausal osteoporotic women. Phase III Osteoporosis Treatment Study Group. *J Clin Endocrinol Metab* 2000; 85(9):3109–15.
- Black DM, Thompson DE, Bauer DC, Ensrud K, Musliner T, Hochberg MC, Nevitt MC, Suryawanshi S, Cummings SR. Fracture risk reduction with alendronate in women with osteoporosis: The Fracture Intervention Trial. FIT Research Group. *J Clin Endocrinol*